

Overview: Green Nail Syndrome

Wayne L. Bakotic, DO
Cutis Diagnostics



Overview: Green Nail Syndrome

Wayne L. Bakotic, DO, Cutis Diagnostics

Green nail syndrome (GNS) is the most common bacterial infection of the nail unit.¹ Both the upper and lower extremities may be affected in GNS, but is uncommonly reported as a primary cause of onychodystrophy. The causative organism, *Pseudomonas aeruginosa*, is a gram-negative bacteria which is ubiquitous in nature favoring warm and moist environments with reservoirs in soil, water, plants and animals. Infection of the nail results in chloronychia as a direct result of the production of pyoverdinin and pyocyanin by *P. aeruginosa*.² The resultant discoloration ranges from yellow-green to green-black depending on the duration of infection as well as compounding pathologies within the nail unit. While very little data exists as to the rate of GNS in the general population, in our preliminary experience, from 2-5% of submitted nail dystrophy cases are positive for *P. aeruginosa* either by culture or molecular genetic analysis, depending on the

method of identification. However, as targeted investigation continues this rate is expected to increase as false negatives are decreased.

Being an opportunistic pathogen, *P. aeruginosa* often gains entry to the nail unit secondary to a concurrent nail pathology. Predisposing conditions include onychomycosis, inflammatory nail disease, diabetes mellitus, paronychia and immunosuppression.¹⁻³ In addition, environmental and occupational conditions also result in an increased susceptibility. Professions in which the nails are chronically exposed to moisture including homemakers, dishwashers, food service workers, gardeners/landscapers and medical professionals are increased risk.²⁻⁴ The most common preexisting pathology associated with GNS is the lifting of the nail plate from the nail bed, onycholysis⁵, which also lends itself to the typical clinical scenario of limited nail

Figure 1. Green Nail Syndrome

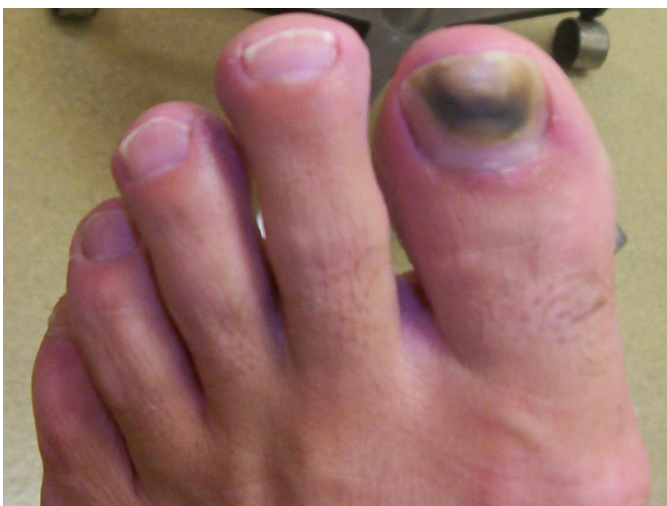

Photo Credit: Dr. Tracey Vlahovic

Figure 2. Green Nail Syndrome

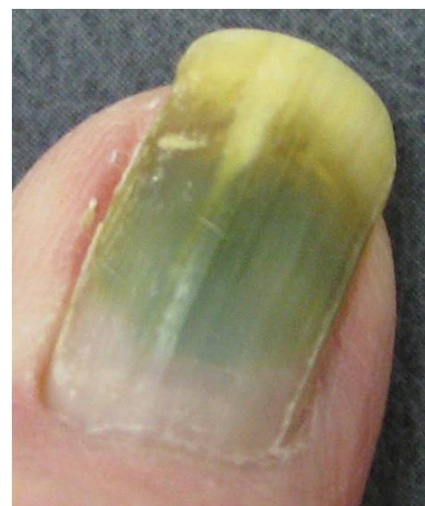

Photo Credit: Dr. Tracey Vlahovic






involvement, typically one or two nails. The onycholytic area results in a potential space which may hold moisture and allow the bacteria to colonize and flourish. Non-pathologic colonization of the nail unit is not a common event given the relatively dry conditions of the healthy nail unit. In the case of GNS, the resultant pigmentary alteration occurs beneath the nail plate and therefore even vigorous washing will not alleviate the issue.

While the chloronychia may be unsightly and potentially mistaken for more consequential diagnoses including melanocytic lesions, such as melanoma⁴, additional complications are also possible. In the immunocompromised, at risk diabetic patient, as well as others, secondary bacterial transfer to chronic wounds or surgical sites or potential paronychia may result in local and/or systemic infections leading to increased complications, hospital stays and morbidity.⁶

Treatment of GNS can be challenging in some cases. While the bacterium itself is treated relatively easily with topical antimicrobials such as bacitracin⁷, the underlying nail pathology can make overall therapeutic success variable. If the concurrent nail unit pathology is not addressed adequately, recurrence is possible. In those cases where conservative therapies fall short, a more complete treatment regimen may be necessary which may include nail removal and the use of systemic antimicrobial agents. Although clinical trials are relatively scarce, oral or topical fluoroquinolones and topical aminoglycosides have been shown to be effective in the treatment of GNS when more conservative methods have failed.⁸⁻¹⁰ In addition, avoidance of continued moisture exposure would also be recommended.

1. Nenoff P, Paasch U, Handrick W. Infections of finger and toe nails due to fungi and bacteria. *Hautarzt*. 2014 Apr;65(4):337-48.
2. D'Agata E. *Pseudomonas aeruginosa*. In: Bennett JE, Dolin R, Blaser MJ (eds). *Principles and Practice of Infectious Diseases*. 8th ed. Elsevier, Saunders; 2015.
3. Tosti A, Piraccini BM: Nail disorders; in Bologna JL, Schaffner JV, Cerroni L (eds): *Dermatology*, ed 4. Elsevier, 2018, pp 1207-1208.
4. Chiriac A, Brzezinski P, Foia L, Marincu I. Chloronychia: green nail syndrome caused by *Pseudomonas aeruginosa* in elderly persons. *Clin Interv Aging*. 2015 Jan 14;10:265-7.
5. DeMartinis NC, Cohen PR. Non-Melanoma-Associated Dyschromia of the Proximal Nail Fold. *Cureus*. 2016 Dec 9;8(12):e922.
6. Wu DC, Chan WW, Metelitsa AI, Fiorillo L, Lin AN. *Pseudomonas* skin infection: clinical features, epidemiology, and management. *Am J Clin Dermatol*. 2011 Jun 1;12(3):157-69.
7. Greene SL, Su WP, Muller SA. *Pseudomonas aeruginosa* infections of the skin. *Am Fam Physician*. 1984 Jan;29(1):193-200.
8. Agger WA, Mardan A. *Pseudomonas aeruginosa* infections of intact skin. *Clin Infect Dis*. 1995 Feb;20(2):302-8.
9. Bae Y, Lee GM, Sim JH, Lee S, Lee SY, Park YL. Green nail syndrome treated with the application of tobramycin eye drop. *Ann Dermatol*. 2014 Aug;26(4):514-6.
10. Müller S, Ebnöther M, Itin P. Green Nail Syndrome (*Pseudomonas aeruginosa* Nail Infection): Two Cases Successfully Treated with Topical Nadifloxacin, an Acne Medication. *Case Rep Dermatol*. 2014 Jul 19;6(2):180-4.



 6240 Shiloh Road, Alpharetta, GA 30005  cutisdx.com
 info@cutisdx.com  855-392-8847  678-807-2945